

Chest sonography images in neonatal r.d.s. And proposed grading

PRADEEP KULKARNI.¹ NIKIT MEHTA.² VASUDHA JADHAV.³

^{1&2}Asso. Professor. Department of Radio-diagnosis,

³Asso. Professor. Department of Anesthesiology, Bharati Medical college & Hospital, Sangli. India. Pin : 416 416.

ABSTRACT : BACKGROUND : Lung sonography has been used to monitor the patients of R.D.S. in N.I.C.U. in recent times.

AIMS : To Describe and Grade the changes of R.D.S. by lung sonography.

SETTING & DESIGN : Tertiary care institutional set up in a rural medical college.

STUDY DURATION : September 2014 to May 2015. Follow-up variable, upto 2 weeks.

PROSPECTIVE, ANALYTICAL STUDY.

MATERIALS AND METHODS -This was a single institute study approved by the institutional ethics committee. Prior informed consent was obtained from the parents. 100 consecutive patients admitted in N.I.C.U. WITH gestational age < 36 weeks with respiratory complaints were enrolled. Chest x-ray was obtained within few hours of admission and lung sonography was performed within 24 hours. Follow – up sonography was performed as and when necessary. Sonography image was graded and correlated with chest xray and clinical picture.

KEYWORDS : B lines (ultrasound lung comets),¹. neonate, respiratory distress syndrome, segmental white lung, transabdominal ultrasound, white lungs.

I. INTRODUCTION

Respiratory distress syndrome is a disease associated with prematurity. Its incidence increases proportional to decreasing gestational age at birth. Globally preterm birth accounts for over 9.5% of births. In India rate of preterm birth is approximately 21 %. Its diagnosis and management so far has been done by clinical features and chest x-ray.² Both these methods are sensitive but there are some limitations.

1. Clinical assesment varies depending upon observer's experience, variable presentation in extreme preterm & extremely low birthweight.
2. Interpretation of the location and nature of opacity on chest X ray is sometimes difficult. Differentiation between pulmonary and pleural lesions may not be possible.³
3. X-rays involve exposure to ionising radiation so either very high radiation dose is required or to avoid radiation dose X-rays can not be repeated as & when required.

Chest sonography is being used extensively in N.I.C.U. due to its advantages. It does not use ionising radiation, it is easy bedside technique, simple to perform and no change is required in neonatal environment. It gives all the necessary information for management and follow – up.⁴

II. SCANNING TECHNIQUE

Sonography was performed from sub-costal approach (trans-abdominal) using liver and spleen as sonic windows for evaluation of lung bases.⁵ Intercostal sonography from lateral axillary approach and posterior axillary approach was sometimes required. Sonosite M – Turbo machine was used, sonography performed with multifrequency paediatric abdominal phased array probe.

III. OBSERVATIONS AND DISCUSSION

In neonates without R.D.S. (normal aerated lungs), chest sonography demonstrated a bright echoreflective line at pleural-lung interface with shadowing beyond. This was appearance of normal aerated lungs. In some neonates few thin white lines (B lines) perpendicular to lung-pleura interface were seen, which we realised was a normal appearance as these neonates were clinically and Radiographically normal.⁶ These lines have been described earlier by researchers as representing sub-pleural interstitial edema. When these lines were thick and numerous neonates were found to be mildly affected clinically.

We agree with earlier authors that B lines represent interstitial fluid.⁷ When this fluid is in sub-pleural location it will cause a break in echo-reflective surface as well as an artefactual line because of reverberation.

Segmental white lung appearance - thick white columns extending from pleural surface. This represented neonates with moderate changes of R.D.S. clinically and Radiologically.

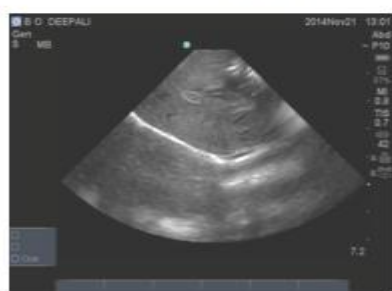Total white lung corresponded with severely affected neonates clinically and Radiologically.⁸

Segmental white lung and white lung is most likely produced by collapsed alveoli, which allow the sound waves to pass through, and because of too many interfaces of collapsed alveoli cause bright appearance. (Similar appearance is found in capillary hemangiomas in liver and infantile polycystic kidneys disease where there are too many interfaces with minimal or no fluid in between)

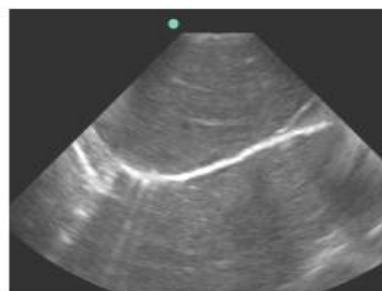
The appearances are overlapping and rapidly changing. We found them to correlate very well with clinical picture. In some cases they correlated with clinical picture much better than the radiographs.

Summary and conclusion :

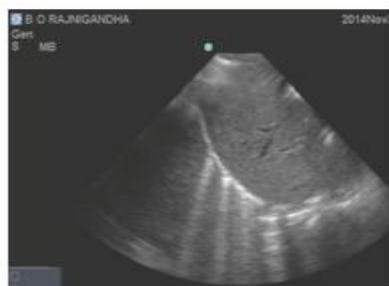
The chest sonography images were graded as follows



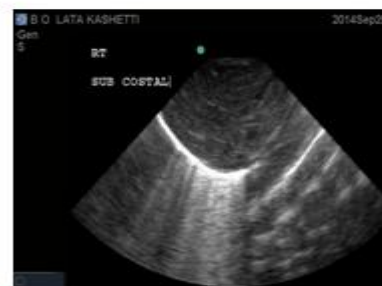
Grade 0 – Normal. Bright line at plura lung interface with shadowing.



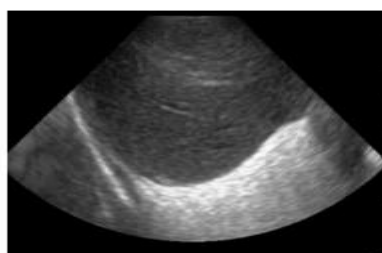Grade 1 – Few B-lines



Grade 2 – Thick numerous B-lines



Grade 3 – Segmental white lung.



Grade 4 – Total white lung

The correlation between sonographic images and clinical picture was excellent. The chest sonography is reliable and better suited for follow – up in R.D.S. because of lack of radiation and more reliable correlation with clinical assesment. In follow-up these changes are very usefull to assess how the neonate is responding to treatment. A visual evaluation based on number and thickness of B-lines permits a semi-quantitative evaluation of the amount of interstitial fluid.⁹ The chest sonography gives reliable evaluation of status of patient and response to management.

Thus it reduces number of Chest X rays required and hence the radiation dose to neonate.¹⁰ It can be repeated as frequently as required anf response to treatment can be very closely monitored.

REFERENCES

- [1] Gino Soldati. Et al. Sonographic Interstitial Syndrome. *J Ultrasound Med* 2009; 28:163–174.
- [2] Raimondi F. Et al. Use of neonatal chest ultrasound to predict noninvasive ventilation failure. *Pediatrics* October 2014. 134(4):e1089-94.
- [3] Ok Hwa kim et al. US in the diagnosis of pediatric chest diseases. *Radiographics* May 2000. Volume 20, Issue 3.
- [4] [Bober K](#). Et al. Diagnostic utility of ultrasonography for respiratory distress syndrome in neonates. [Medical science monitor : international medical journal of experimental and clinical research](#) 12:10 2006 Oct pg CR440-6
- [5] Chirag kumar Ahuja et al. Role of transabdominal ultrasound of lung bases and follow-up in premature neonates with respiratory distress soon after birth. *Indian journal of Radiology and Imaging*. 2012 volume 22 Issue 4.
- [6] Liu, Jing et al. Diagnosis of neonatal Transient Tachypnoea and its Differentiation From Respiratory Distress Syndrome Using Lung Ultrasound. *Medicine* December 2014. Volume 93 Issue 27.
- [7] Andrea Smarglassi et al. The role of chest sonography in the management of respiratory diseases : document II. *Multidisciplinary Respiratory Medicine* 2013, 8:55
- [8] Asha Daabis. Et al. Relevance of chest sonography in the diagnosis of acute respiratory failure: Comparison with current diagnostic tools in intensive care units. *Egyptian Journal of Chest Diseases and Tuberculosis* Volume 63, Issue 4, October 2014.
- [9] Corradi F et al. Chest ultrasound in acute respiratory distress syndrome. [Curr Opin Crit Care](#). 2014 Feb;20(1):98-103.
- [10] Daniel Lichtenstein, et al. Comparative Diagnostic Performances of Auscultation, Chest Radiography, and Lung Ultrasonography in Acute Respiratory Distress Syndrome. 2004. *The Journal of the American Society of Anesthesiology*.