

Congenital Agenesis Of The Corpus Callosum With Intracerebral Lipoma And Frontal Encephalocele Presenting As A Case Of Unresolved Anterior Fontanel Swelling: A Case Report

Kiridi EK ¹, Dambo ND ²

1. (MBBS, Msc, FWACS)Radiology department, Niger Delta University Teaching Hospital, Okolobiri, Bayelsa State.

2. (MBBS, MPH)Hospitals management board, Yenegoa, Bayelsa State.

I. INTRODUCTION

Integration between the right and left cerebral hemispheres of the brain is important for proper function of the sensory, motor and higher cognitive activities. The corpus callosum which is the largest commissure in the brain is responsible for this integration¹. Its absence is associated with both clinical and social problems². The corpus callosum begins to form as early as the sixth week of gestation and by birth, the number of callosal fibres is already fixed with structural changes occurring in the post natal period^{2, 3} and growth occurring in puberty⁴.

Agenesis of the corpus callosum is one of the most common malformations of the human brain^{2, 5}. While several genetic causes have been associated with its occurrence, exogenous causes such as maternal alcohol intake and maternal phenylketonuria have been implicated.

The diagnosis of this condition may be made antenatally with either an ultrasound scan (USS) or magnetic resonance imaging scan (MRI). On USS, a diagnosis of agenesis of the corpus callosum is made when the structure is not visualized. Imaging of the corpus callosum is best done in the mid sagittal or mid coronal planes. In the mid sagittal plane, the corpus callosum is identified as thin anechoic space, lined superiorly and inferiorly by two echogenic lines. The peri-callosal artery may be used as a marker⁶. Features that are suggestive of agenesis of the corpus callosum include; absence of the cavum septi pellucidum, abnormalities of the ventricles, widening of the inter-hemispheric fissure and radial disposition of the sulci on the internal aspects of the hemispheres^{6, 7}. MRI is thought to be superior to USS in making a diagnosis of agenesis of the corpus callosum as USS has been associated with a false positive rate of up to 20% , MRI can differentiate between partial and complete agenesis and has the ability to find features that may not be seen on USS⁶.

Postnatally, an USS, computed tomography (CT) scan or MRI may be used. MRI is the preferred imaging modality as it has a greater sensitivity in depicting cerebral anomalies⁷.

We present a 3day old female neonate who was noticed to have a swelling of the anterior fontanel shortly after delivery. Clinically, it was thought to be caused by raised intracranial pressure. CT scan of the brain revealed absence of the corpus callosum with frontal encephalocele and mid brain lipoma.

II. CASE REPORT

AO is female who was brought to the Niger Delta University Teaching Hospital with unresolved anterior fontanel swelling 3 days after delivery by her parents.

The mother had antenatal care in a private hospital. It was uneventful and she took no drugs other than her routine drugs in this period. She did not take alcoholic beverages, use tobacco or recreational drugs. She had a spontaneous vaginal delivery at term after a normal labour. The baby cried immediately after delivery.

The baby was then referred to the Niger Delta University Teaching hospital for expert care when the anterior fontanel was noticed to be bulging. An initial diagnosis anterior fontanel swelling secondary to raised intracranial pressure and possible hydrocephalus was made.

Ultrasound sound access through the anterior fontanel produced poor inconclusive images due to obliteration of the acoustic window by centrally placed amorphous calcifications. The posterior fontanel was not assessable.

The scout image of the CT scan showed marked swelling of the anterior fontanel. Axial slices revealed complete absence of the corpus callosum which was replaced by a large hypodense lesion with HU of -115 in keeping with lipoma. A huge large amorphous calcification was seen within the lipoma. The anterior and posterior fontanels were seen but deformed. Axial slices and sagittal reformatting showed extrusion of brain tissue through the anterior fontanel. A diagnosis of agenesis of the corpus callosum with mid line intracerebral lipoma and frontal encephalocele was made. The neonate is presently being managed by the paediatric unit.

Figure 1. Scout radiograph showing anterior fontanel swelling.

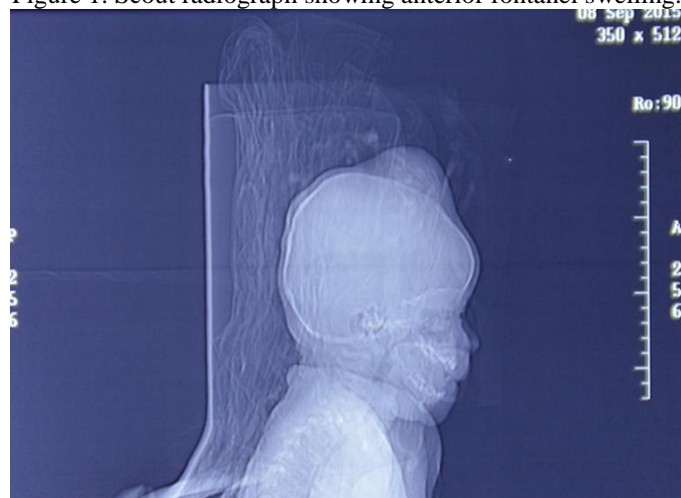


Figure 2 (left image): Axial CT scan image showing dilated posterior horns of the lateral ventricles. (right image): Axial CT scan image showing pointed anterior fontanelles of the lateral ventricles. #Both images show of a large area of central hypodensity having an HU of -115 amorphous calcification within it.

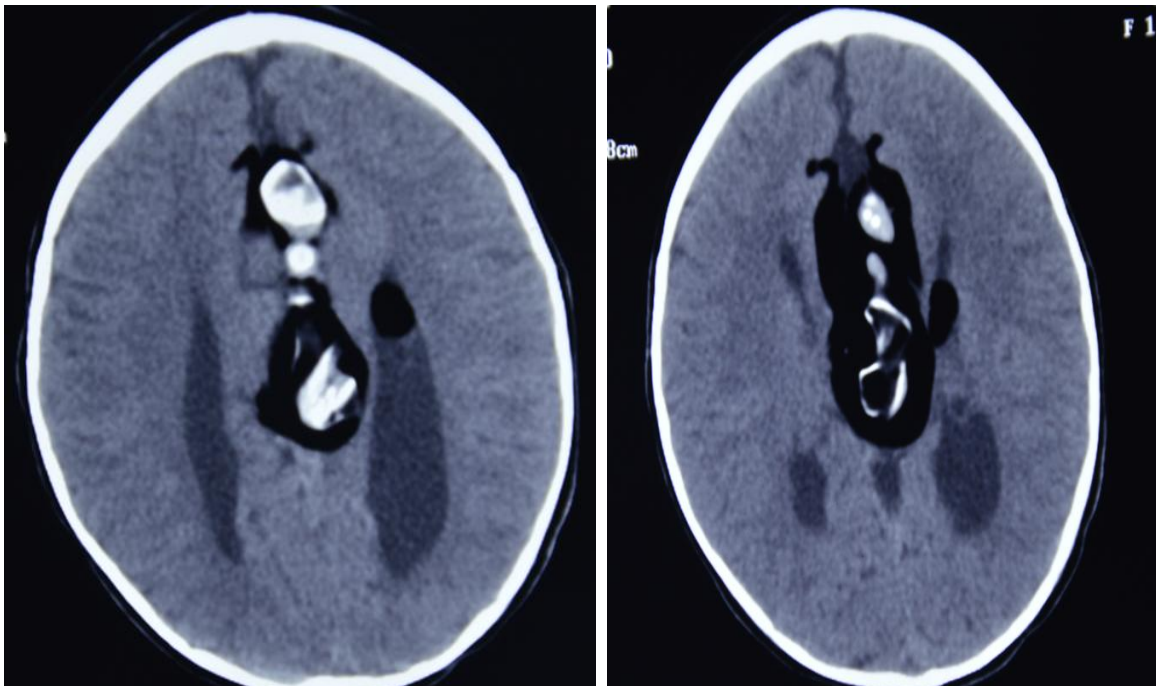
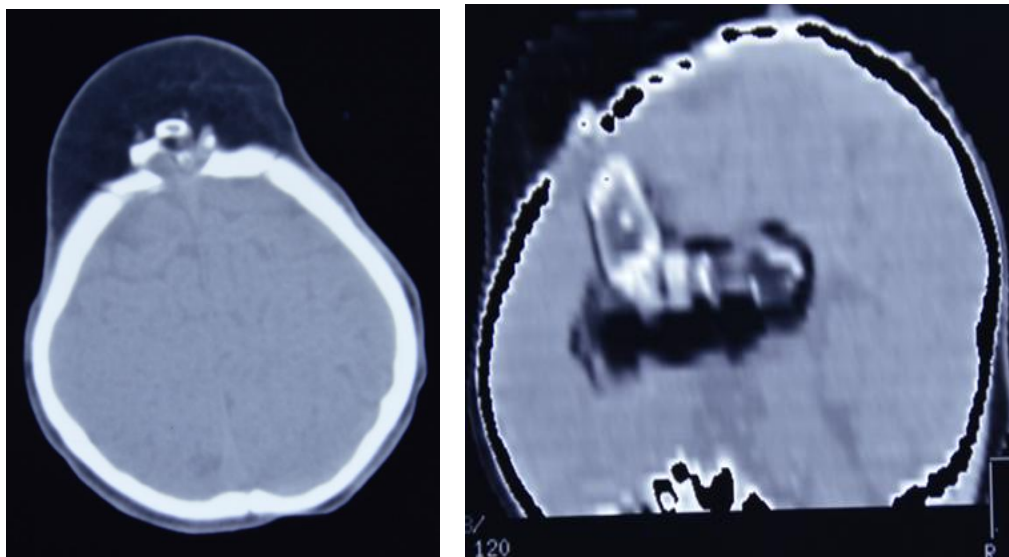


Figure 3. Axial slices and sagittal reformats showing protrusion of brain tissue through the anterior fontanel



III. DISCUSSION

While agenesis of the corpus callosum has been described as being one of the common brain malformations², its incidence in Nigeria is undocumented. This may be due to the paucity of the required imaging equipment, dearth of skilled personnel and poor use of health facilities by patients.

While the MRI has been described as the best imaging modality for use in cases of agenesis of the corpus callosum, a CT scan was what was available to us. CT findings in this condition include; parallel appearing lateral ventricles, colpocephaly (dilated posteriorly) and pointed frontal horns. Variable findings include a midline cyst or a lipoma⁸. Colpocephaly, pointed frontal horns and a lipoma were seen in our patient. Differential diagnosis include periventricular leukomalacia, lobar holoprosencephaly and hydrocephalus. Chiari 2 malformation has been associated with colpocephaly⁸.

While there has been an increase in the number of Nigerian women assessing antenatal imaging by way of ultrasound scans in recent times, antenatal imaging is still largely unregulated as there are no national guidelines on the antenatal imaging and a large number of people offering the service do not have the required knowledge and skill needed for obstetric imaging⁹. A mid trimester scan has the ability to point out this abnormality^{6,7} depending on when it occurred and the parents of the baby would have been properly counselled. The clinical presentation in this condition varies and may be mild in which the patient may have learning difficulties or severe in which the patient may have significant neuropsychiatric deficit¹⁰. Management depends on the clinical features that are present and may require multidisciplinary care.

IV. CONCLUSION

This presentation serves to highlight the role of radiology in the prenatal diagnosis and its importance in the management of patients. AO had initially been thought to have a hydrocephalus and this was clarified with the use of a CT scan. There are very few facilities for advanced imaging in our setting¹¹ and this persistently serves as a drawback to adequate patient care. Also there is a need for urgent regulation for radiologic practice in Nigeria with emphasis on qualification of practitioners. This will help clinicians in counselling patients especially when prenatal diagnosis is required.

CONSENT

Consent was given by the parents of AO for images to be used in this publication.

COMPETING INTERESTS: None

REFERENCES

- [1]. Derbali F, Ben Fradj F, Rezgui A, Karmani M et al. The Corpus Callosum Agenesis. *American Journal of Medical Case Reports*. 2015; 3(2):27-29.
- [2]. Luders E, Thompson PM, Toga AW. The Development of the Corpus Callosum in the Healthy Human Brain. *The Journal of neuroscience: the official journal of the Society for Neuroscience*. 2010; 30(33):10985-10990. doi:10.1523/JNEUROSCI.5122-09.2010.
- [3]. Schell-Apacik CC, Wagner K, Bihler M, et al. Agenesis and Dysgenesis of the Corpus Callosum: Clinical, Genetic and Neuroimaging Findings in a Series of 41 Patients. *American journal of medical genetics Part A*. 2008; 146A(19):2501-2511. doi:10.1002/ajmg.a.32476.
- [4]. Chavarria MC, Sánchez FJ, Chou Y-Y, Thompson PM, Luders E. Puberty in the Corpus Callosum. *Neuroscience*. 2014;265:1-8. doi:10.1016/j.neuroscience.2014.01.030.
- [5]. Chiappedi M, Bejor M. Corpus callosum agenesis and rehabilitative treatment. *Italian Journal of Pediatrics*. 2010;36:64. doi:10.1186/1824-7288-36-64.
- [6]. Santo, S., D'Antonio, F., Homfray, T., Rich, P et al. Counseling in fetal medicine: agenesis of the corpus callosum. *Ultrasound Obstet Gynecol*, 2012;40: 513–521. doi: 10.1002/uog.12315
- [7]. Singh S, Garge S. Agenesis of the corpus callosum. *Journal of Pediatric Neurosciences*. 2010;5(1):83-85. doi:10.4103/1817-1745.66662
- [8]. Jones BV. *Callosal dysgenesis in Diagnostic Imaging Pediatrics*. Donnelly (editor) 2005. Amirsys, Utah.
- [9]. Enakpene CA, Morhason-Bello IO, Marinho AO, et al. Clients' reasons for prenatal ultrasonography in Ibadan, South West of Nigeria. *BMC Women's Health*. 2009;9:12. doi:10.1186/1472-6874-9-12.
- [10]. Chiappedi M, Fresca A, Baschenis IMC. Complete Corpus Callosum Agenesis: Can It Be Mild? *Case Reports in Pediatrics*. 2012;2012:752751. doi:10.1155/2012/752751.
- [11]. Kiridi EK, Madufuro GOC, Dambo ND. Craniocerebral CT Findings in Patients with Clinically Diagnosed Stroke in Yenagoa Bayelsa State Nigeria. *AASCIT Journal of Medicine*. 2015; 1(3): 43-45.