

## Unna nevus of the scalp: Unusual clinical presentation

Aziz A. Al-Sohaimi<sup>1</sup>, Hasan S. Alghamdi<sup>2</sup>, Abdulrahman H. Alghamdi<sup>3</sup>,  
Abdullah H. Alghamdi<sup>3</sup>, Fares A. Alzahrani<sup>3</sup>, Ali A. Alghamdi<sup>3</sup>, Khalid S.  
Alghamdi<sup>3</sup>

(1Assistant Professor of Dermatology, Faculty of Medicine, Al-Baha University, KSA. Email; (2Consultant Dermatologist, Ministry of Health, KSA (3 Medical Student, Faculty of Medicine, Al-Baha University, KSA)

**Abstract:-** The term "dermal melanocytic nevi" includes a group of clinically and histopathologically distinct subtypes, including Miescher's nevus, flat nevus, and Unna's nevus. Flat nevi are the most common clinical type. Miescher's and Unna's nevi have different clinical and histopathological features, making them easily distinguishable. We present a case of an Unna's nevus in the posterior of the scalp with unusual localization.

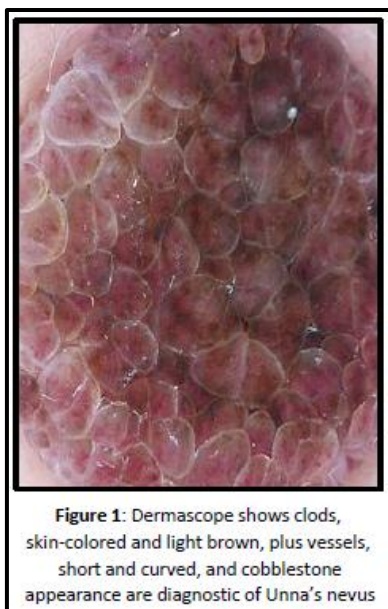**Keywords:-** Unna's nevus; posterior of the scalp; Miescher's nevus; flat nevus.

### I. INTRODUCTION

The term "dermal melanocytic nevi" includes a group of clinically and histopathologically distinct subtypes, including Miescher's nevus, flat nevus, and Unna's nevus [1]. Flat nevi are the most common clinical type. They are most commonly found on the trunk and the extremities. Miescher's nevi are mostly found on the scalp, face, and neck. Unna's nevi are mainly found on the trunk and show a maximum incidence between the ages of 70 and 79 years.

### II. CASE REPORT

A 24-year-old male presented with an Unna nevus in the posterior of the scalp complaining of an exophytic polypoid nodule in the back of the scalp present since childhood. Consent was obtained. Dermoscopy as shown in (Fig. 1)

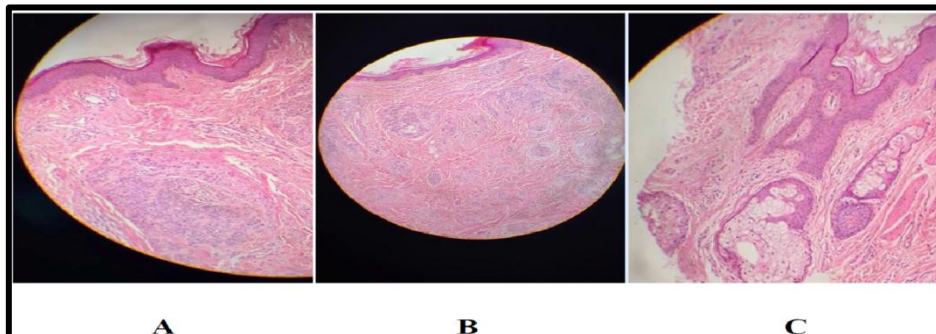


Physical examination revealed a well-defined exophytic nodule 1.5 × 1.5 cm in diameter (Fig. 2)

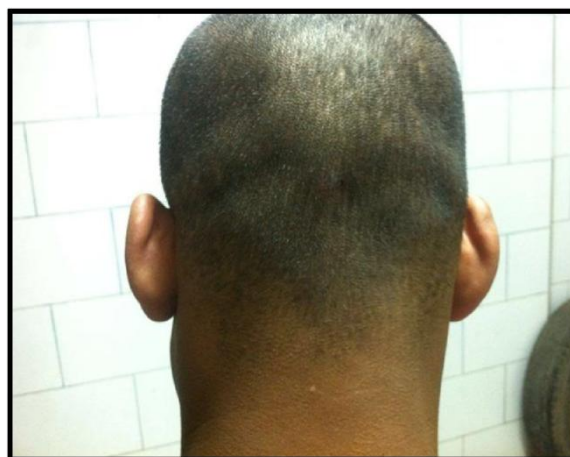

**Figure 2:** Exam showed well-defined exophytic nodule in the posterior scalp

Histopathology revealed papillomatosis as shown (Fig. 3A). Multiple nests of melanocytes were located intradermally, and associated with a pattern of cords, strands between collagen bundles, and nests of melanocytes within the papillary dermis (Fig. 3 B and C).



**Figure 3:** Nesting of multiple melanocytes, cords, and strands involving the dermis without junctional activity. Melanocytes nesting in the dermis are easily seen. Total excision was done without recurrence after 6 months of follow up (Fig.4)



**Figure 4.** After 6 months of treatment

### **III. DISCUSSION**

The term “dermal melanocytic nevus” includes two clinical dermatoscopic and histopathologic variants of benign dermal melanocytic nevi, Unna nevus (dermal melanocytic nevus with papillomatosis) and Miescher nevus (facial derma nevus with flat surface) [2]. Clinically, Unna nevus usually presents as a soft polypoid or sessile skin color; hyperpigmentation also sometimes appears on the trunk, both arms, or in the neck region, but rarely on the scalp. At clinical presentation, Miescher nevi are rather firm, dark brown to nearly skin-colored, dome-shaped, flat surface papules and plaques with facial predominance [4]. Unna nevus clinically resembles seborrheic keratosis [3]. Dermatoscopically, Unna nevi have a globular pattern with multiple light-colored to brown, round globules that are distributed all over the lesion, or a pattern of cobblestoning that consists of large clods, skin-colored and light brown. Short, curved vessels are also an indication to the diagnosis of Unna nevus

### **REFERENCE**

- [1] 1-Yus ES, del Cerro M, Simón RS, Herrera M, Rueda M. Unna's and Miescher's nevi: two different types of intradermal nevus: hypothesis concerning their histogenesis. *Am J Dermatopathol.* 2007;29:141-51.
- [2] 2- Witt C, Krengel S. Clinical and epidemiological aspects of subtypes of melanocytic nevi (Flat nevi, Miescher nevi, Unna nevi). *Dermatology Online Journal* 2010;16 (1)
- [3] 3- Kerl H, Cerroni L, Ackerman B. Pitfalls in Histopathologic Diagnosis of Malignant Melanoma 1st edn 1994: 46-47.
- [4] 4-Braun-Falco, O., Plewig G, Wolff H, Burgdorf W. *Dermatology.* 2<sup>nd</sup> edn , Chapter 58.