

Ankylosing Spondylitis: Review and Current Treatments.

Mr. Saurabh Rajkumar Jadhav.*

Final year B.pharmacy of shreesaraswati institute of pharmacy , tondavali, kankavli , sindhudurg, Maharashtra.

Dr. babasaheb ambedkar technological university, lonere ,raigad, Maharashtra.

Received 21 February 2021; Accepted 6 March 2021

ABSTRACT:-

Bamboo spine also known ankylosing spondylitis (AS) .most of medical experts said that on this medical condition there is no such effective medicine to cure completely but it can be controllable adverseness of disease.

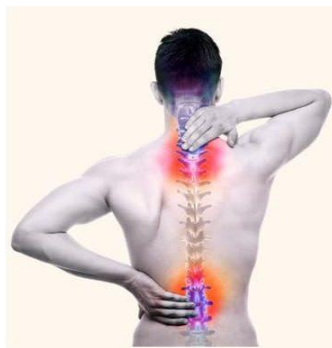Rheumatism it's a type of autoimmune disorder under which AS is comes. in this our immune system strikes on our healthy cells results into severe pain and inflammatory conditions , stiffness, and loss of motions.

Ankylosing spondylitis also known as ankspond . its affects most of axial skeleton such as ,pelvic girdle, lumbar L1 to L5 vertebrae, upper thoracic ,neck ,and after progression it's also affects on shoulder and groin region as well. and this medical belongs to rheumatism (SpA).

Presence of HLA-B27 gene which is diagnostically confirmed in 80 -90% of AS patient. It is done through a simple blood test in any pathology lab. The gene HLA-B27 is genetically present in our body so it's a lifelong hereditary medical condition progressively get worsen.

On this medical condition medical experts arranged treatment such as to reduce or prevent the pain as well inflammation which causing body stiffness and loss of mobility.

KEYWORDS:- ankylosing spondylitis, rheumatism, HLA-B27,hereditary ,etc.



I. INTRODUCTION:-

Rheumatoid arthritis(1) it's a type of autoimmune disorder genetically present in human body. Ankylosing spondylitis(2) it's a disease condition comes under this .Pain and inflammation to the axial skeleton(3) started in initial days. Its main sign and symptom of the AS .progressively pain is get worsen in knee joint and lumbar(4) and pelvic region(5) and body gets stiffened day by day . as the progression in this condition patient gone through severe joint pain during night and morning stiffness occurs for at least 30 min.(6)

In this condition most of vertebrae column (7) get affected , initially its started from lumbar and pelvic vertebrae. And progressively the ligaments and tendons(8) affected and start deformed. Calcium deposition(9) in the joints lead to formation of new bone called osteogenesis(10).and cause bamboo spine in advance cases.

Gender difference in AS the study says that most of the males are prone to this condition than women's in the ratio is 3:1(11). This condition generally occurs at the age of 15 to 45 yr.

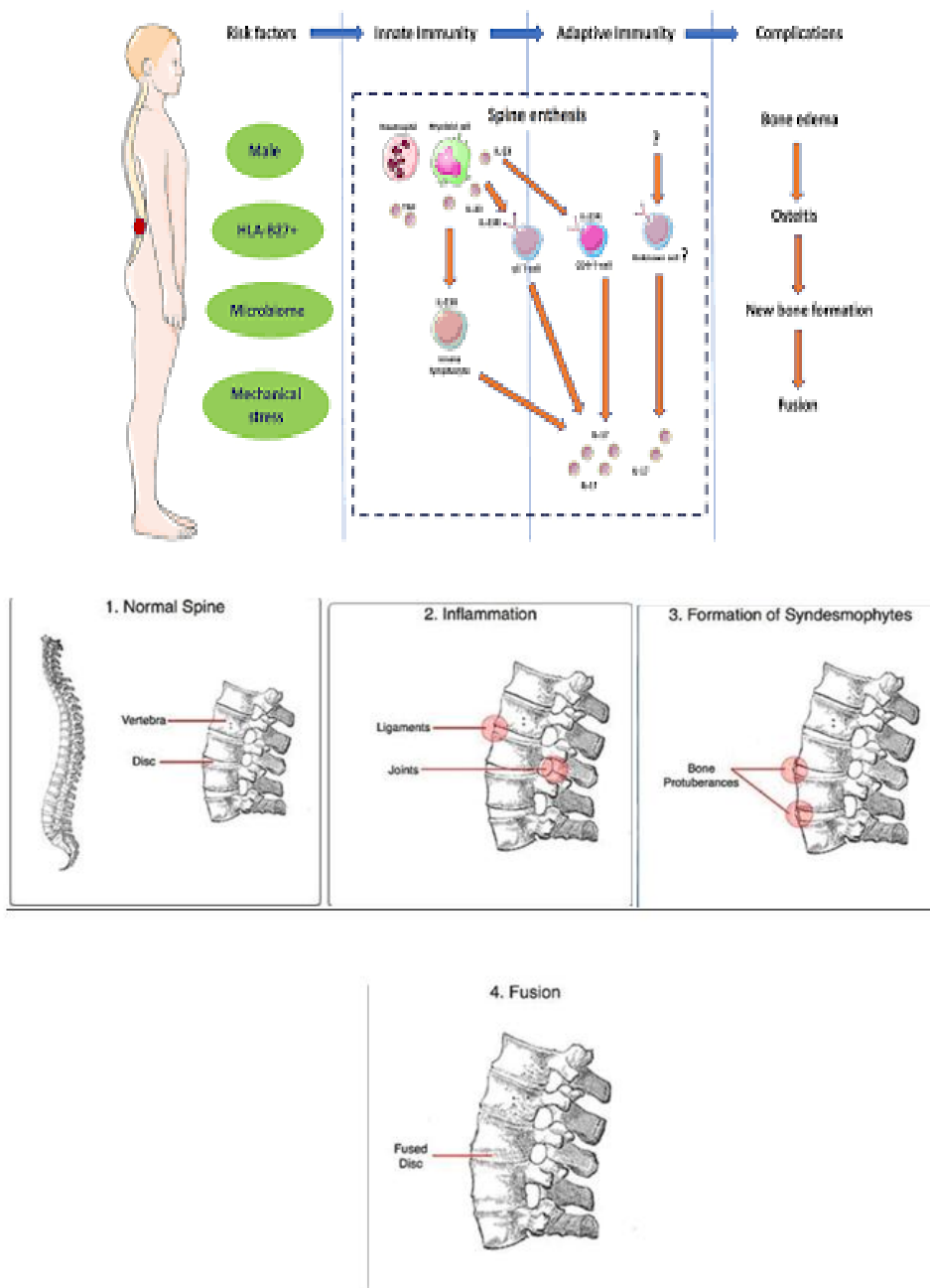


fig.no.-1-4 progression of ankylosing spondylities.

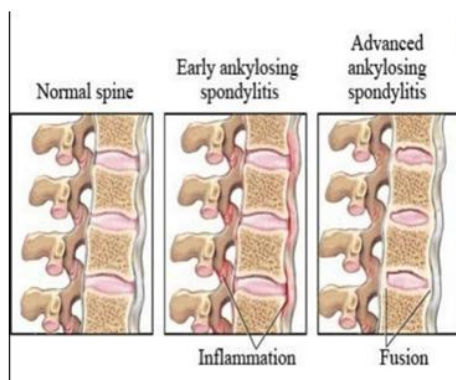


DIAGNOSTIC STUDY:-

In earlier studies noticed that signs and symptoms like pain in joints inflammations to the most of axial parts , and difference occurs in walking and decrease in mobility. Which is diagnosed by x-ray imagining (12) and magnetic resonance imaging (MRI)(13). Now it's surely confirmed by presence of HLA-B27 gene(14) by blood test. By X-ray studies its shows that progression of disease and change in spine structure.

Adverseness of this condition can be diagnosed and common disorders occurs such as –

- Rheumatoid arthritis
- Formation of new bone (ontogenesis)(15)
- Degeneration of vertebral disc
- Fractures in bones (16)
- Spinal stenosis(17)
- Inflammation to the bowel
- Reiter's syndrome(18)



ETIOLOGY:-

Mainly rheumatoid arthritis is the core medical condition for AS. In this interaction between genetic factor , history of patient and environmental parameters are affected(19). Study shows that immune reaction ,microbial infection,(20) and loss of mobility occur.

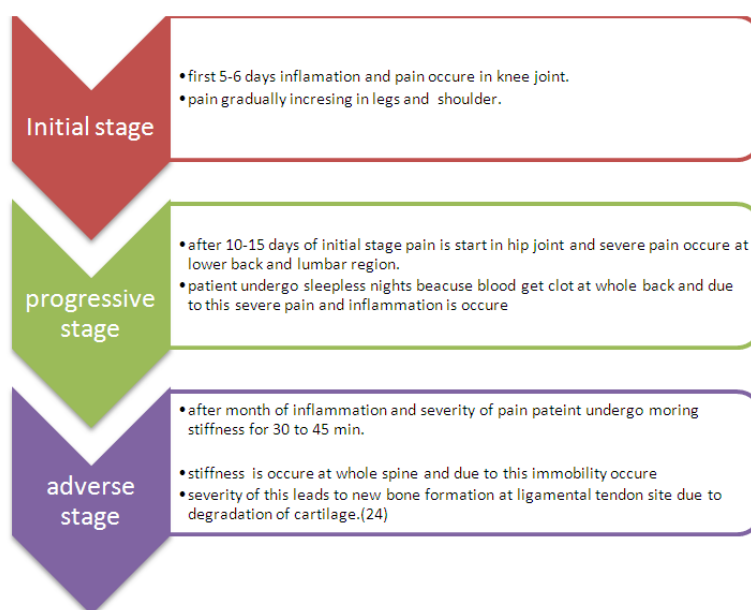
Ankylosing spondylitis directly linked between HLA-B27 gene (human leukocyte antigen). 80-90% of patients are diagnostically confirmed presence of this gene(21).

Synovial fluid between two bones which reduce friction of bones between cartilage this synovium tissue get affected and there is infiltration by macrophages and lymphocytes(22). And due to this it started degeneration of cartilage and formation of bone .known as bamboo spine(23).

CHARACTERISTICS OF BACK PAIN:-

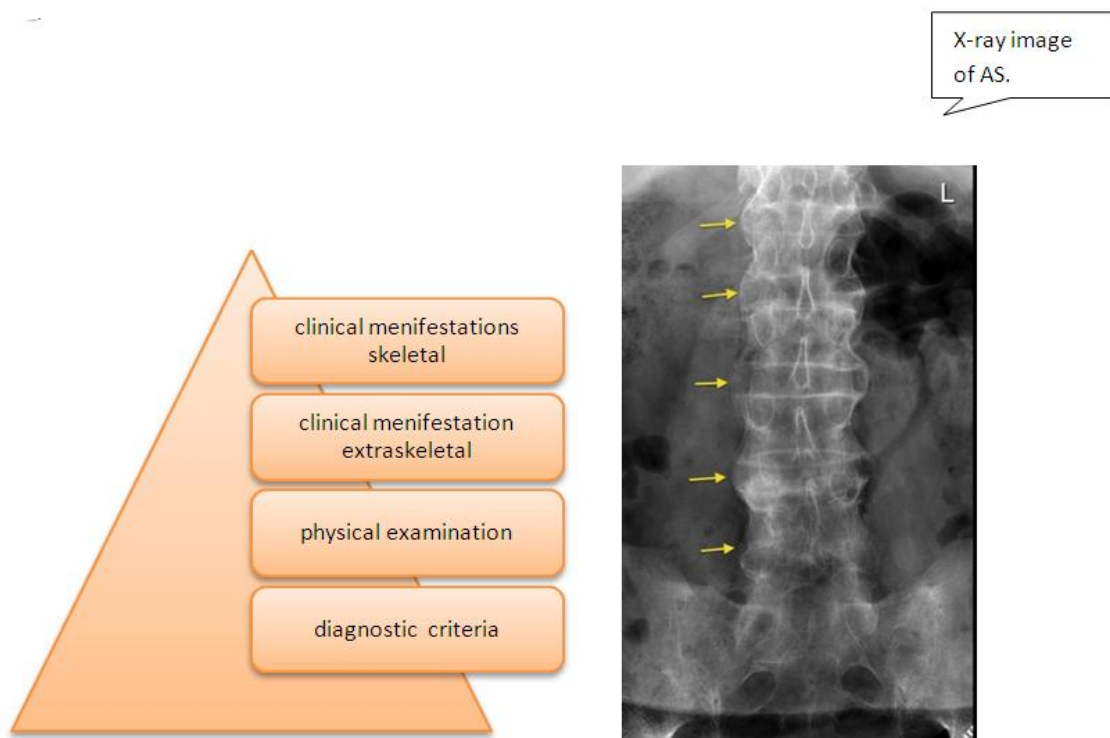
Back pain is the major sign of rheumatism specially in ankylosing spondylitis. Back pain gradually increases at hip joint also known as sacroiliac joint where spine and hip bone joints together and severity of this affects entire spine. Few of major characteristic of back pain:-

- Age :- it's started at the age of early 20's to 45yrs.
- Its mainly occur in men than women.
- Pain and inflammation remain for 3 months.
- At morning stiffness is occurred at spine for 30 min.
- Difficulty in walking and running.
- Immobility in actions.
- Headache fever and fatigue can occur.





DIAGNOSTIC TESTS:-



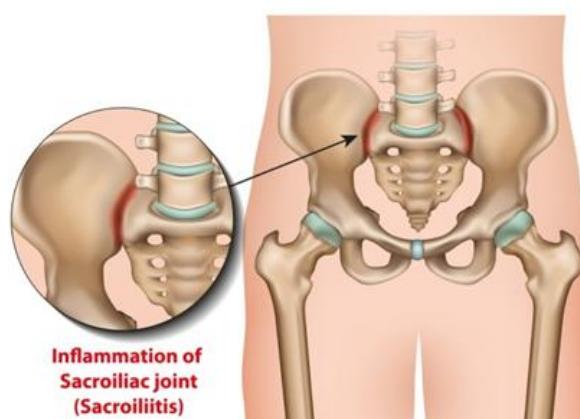
The diagnosis of ankylosing spondylitis can be examined by physical conditions as well as mobility actions of patient. There are no such exact signs and symptoms of AS. Physicians conclude that by family history, physical examination, magnetic resonance image (MRI), X-rays etc.

Confirmation of HLA-B27 gene gives surety of AS; it's done through a simple blood test in any pathology lab.



SEVERITY OF DISEASE CAN BE DIAGNOSED BY-

- Neck disability index (NDI) (25)
- Schober test (26)
- Visual analogue scale (27)
- Oswestry disability index (ODI) (28)



Evaluation scales:-

By pathological examination, values of CRP are used to examine the effectiveness of medicines.

- Bath ankylosing spondylitis metrology index (BASMI) (29)
- Revised leads disability questionnaire (RLDQ) (30)
- BAS-G index (31)

- AMOR criteria for spondyloarthritis(32)
- European quality of life(EuroQoL)(33)

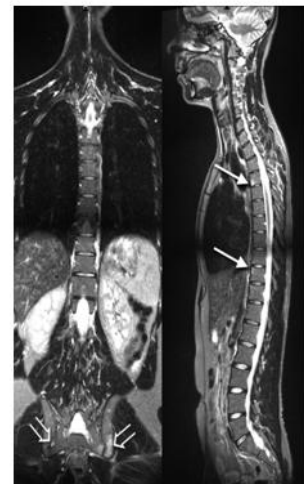
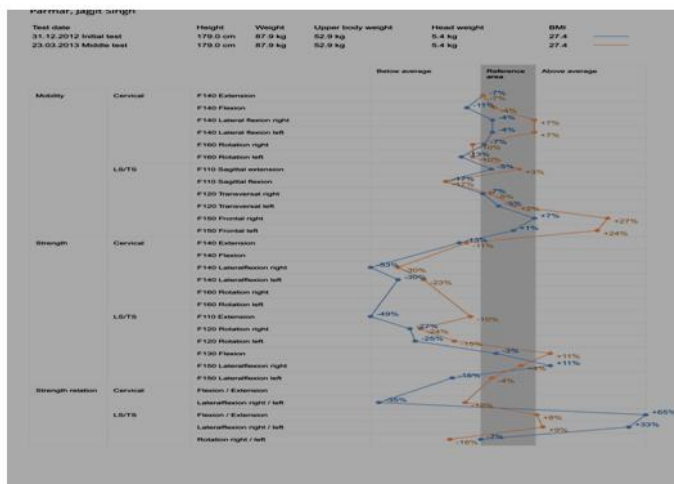


CASE STUDY:-

A 21 yr young male patient had lower back pain and spinal stiffness at morning from last 6 yrs. Patient suffering from intensive pain and inflammation episodes during night as well at morning.

After discuss with physician he arranged medication as per the symptoms(34) to relive pain and inflammation for 15 days . still patient suffering from same condition then he diagnosed by HLA-B27 blood test which is positive test for ankylosing spondylities. After the confirmation physician arranged the treatment on the basis of severity . he gave methyl prednisolone (predmet 8mg) for 1 month but in reducing dose. Because of the steroids are highly addictive in nature.

Physician also arranged some advance treatment by physiotherapist and he gave some physical activity and exercises for mobilize the stiffen part specially exercise for lower pack and thoracic vertebrae. Physiotherapy experts did DSA test (digital spine analysis) through which they examine the condition of spine after 8 yrs of AS history .and arranged whole treatment according to that. DSA test(35) conclude that weakness of muscles and muscle strength. Here showing some medical reports of patient,



A report shows that patient having less mobility at cervical F140 flexion as well difficulty during rotation at right F110 flexion, as per the strength he had 53% weak muscles at cervical region as well 49 % left to right extension which means they have to improve the strength of muscle by particular exercises.(36)



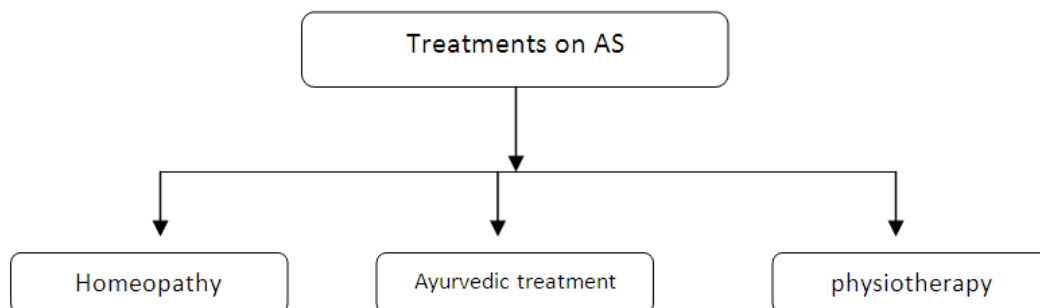
Conclusion:-

patient having AS suffering from lots of severe and unbearable pain in day to day life . continuously taking high power of medications gives harm to the internal body organs and leads to kidney failure , stomach ulcers etc. to prevent that medication physiotherapy is the long term and 0% of side effects to the patient so its beneficial to the patient to mobilize the stiffen parts and relive from the pain.



TREATMENTS ON ANKYLOSING SPONDYLITIS:-

As per the above discussion and etiology there are no such medication to cure this disease condition completely but it can be overcome the harness and treat the symptoms by various methods.

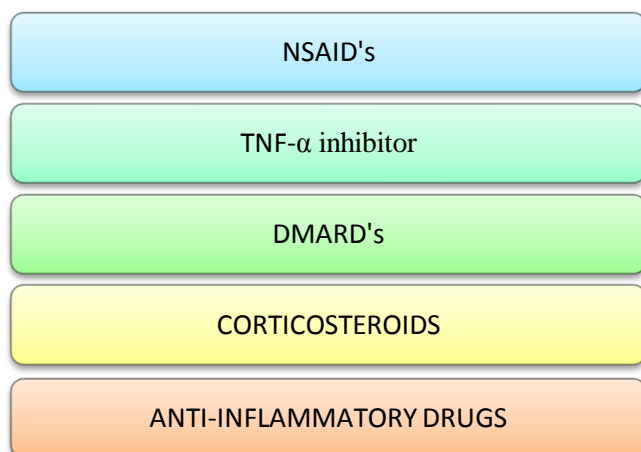


HOMEOPATHIC MEDICINES:-

On ankylosing spondylitis the first line treatment given by physicians are to treat the symptoms like reduce pain and inflammation. on basis of that medicine like pain killers are given to the patient as per the severity . paracetamol is first line drug on to reduce pain this medicine given trice a day for 3 days . Pain killer or anti-inflammatory drugs like diclofenac paracetamol , diclofenac sodium is given to the patient for severe pain due to its side effects physician avoid to prescribe this medication for long time period.

FIRST LINE DRUG TREATMENT:-

First line drug treatment on AS is to reduce inflammation and stiffness of the joints and more importantly spine .



• **NSAID's:-**

Non –steroidal anti-inflammatory drugs are first line drug therapy prescribed by physician on AS. It helps to reduce the inflammatory conditions like pain and body stiffness of the vertebral column. The drugs mainly used for AS are *diclofenac, naproxen, methothrexate, sulindac, tolmetin*. Etc.

• **CORTICOSTEROIDS:-**

Corticosteroids are the drugs used for reduce severe inflammatory condition and unbearable pain and stiffness. The drugs are mainly used are methyl *prednisone, prednisolan*,etc. are in reducing dosage.(37)

• **TNF-α INHIBITORS:-**

Tumor necrosis factor (38) inhibitors are the drugs used for AS have an abundance of pro-inflammatory cytokine tumor necrosis factor RNA and proteins in the joints(39). Its inhibit the release of TNF-α will reduce the inflammatory condition.

The drugs mainly used for AS are *infliximab , Etanercept*.etc

• **DMARD's:-**

In severe conditions where NSAID', steroidal injections(40) are refractory then drug modified anti- rheumatic drugs are prescribed.

The drugs mainly used are *methotrexate, sulfasalazine* etc. are effective on peripheral joint treatment.



AYURVEDIC TREATMENT ON ANKYLOSING SPONDYLITIS:-

DOSHA's IN AS:-

In Ayurveda Doshas are first to look in to it , according to condition and symptoms of AS there are two Doshas are mainly considered.(41)

➤ KAPHA:-

- Stiffness
- Blockage of nerve channels
- Loss of mobility

➤ VATA:-

- Muscle spasm
- Tissue destruction
- Stuck in movements

Ayurvedic medicines are more beneficial on the treatment on ankylosing spondylitis. For long duration with minimal side effects . many experts suggest for the ayurvedic treatment and because of the long duration it will give result after a required dose of drug.

❖ **PANCHAKARMA** is the treatment which helps to removing the unwanted toxins , such as(42)

1. *Virechana* or *basti* (43) these are help into removal of toxins from the body. The duration of this takes 14 -20 days vary from different medical condition.
2. *Some medicines from ayurveda*

DRUGS	DOSE	DURATION
Ashvagandha +milk	3gm twice a day	2 months
Rasrajrasa +Honey	100mg twice a day	2 months
Pippali churna +Honey	1gm twice a day	2 months
Eranda moola +milk	2gm twice a day	2 months



PHYSICAL THERAPY:-

Now a days AS is treated with no medication which is help in long duration and less side effects with an physical and occupational treatment reduces deformity.

Exercise programs :-

➤ Physiotherapist arranged treatments and exercise to reduce stiffness and strengthen the muscles which are damaged surround to the lower back as well as joints.and prevent disability and minimize the risk.



➤ Deep breathing exercise help the thoracic cage flexible which prevent from the complications .



➤ Swimming is the excellent form of exercise for people on AS.

- Swimming
- Yoga
- Jogging
- Deep breathing exercise
- Prone lying
- Badminton



CURRENT ADVANCE TREATMENT ON AS:-

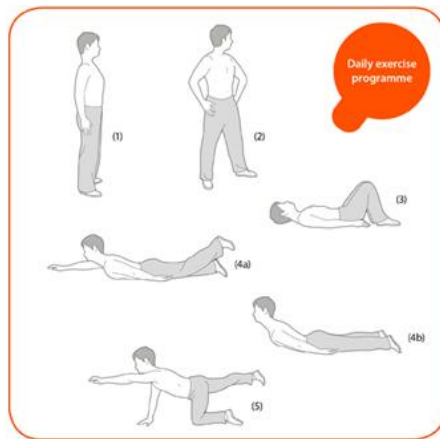
ELECTRO THERAPY:-

Transecutaneous electric nerve stimulation are the advance treatment used now a days which is non surgical as well less side effects of that, its passes the electrical micro current to the body which helps to circulation of blood which reduce inflammation and pain. It's also known as cell repair therapy. Most of physiotherapy clinics arranged separate sessions as per the condition.(44)



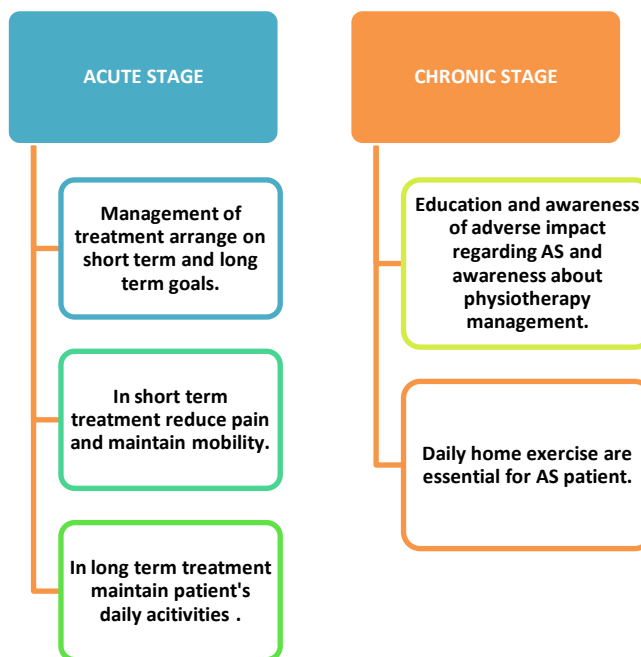
New medication on treatment on AS:-

- ustekinumab (Stelara), an IL12/23 inhibitor.
- tofacitinib (Xeljanz), a JAK inhibitor.
- secukinumab (Cosentyx), an IL-17 inhibitor and humanized monoclonal antibody.
- ixekizumab (Taltz), an IL-17 inhibitor.



Some physiotherapy exercise for ankylosing spondylitis.

OBJECTIVES:-



II. CONCLUSION:-

Rheumatoid arthritis is the medical condition on which there are no such specific medicine to cure completely. As it's a autoimmune disorder majorly impact on spine and sacroiliac joint and started deforming the posture of patient. Awareness regarding AS plays an important role on it which may help to patient's mental health . sometimes peoples judge by its physical appearance and underestimate him/ her so education and awareness is very important.

Physical movement and various exercise improve patients mobility and body function. To reduce pain and inflammation there are many approaches as per the condition of patient's illness. Physiotherapy play an important role which is no side effects to the body and improve patient's mobility . Daily home exercise improve patient's body function which help to live a healthy life . yes! It's not curable but it's controllable.

REFERENCES:-

- [1]. Behzad Heidari, Caspian J Intern Med.Rheumatoid Arthritis: Early diagnosis and treatment outcomes 2011 Winter; 2(1): 161–170
- [2]. Farrouq Mahmood,¹*Philip Helliwell²1. Bradford Teaching Hospitals, Bradford, UK
2. Leeds and Bradford Teaching Hospitals, Bradford, UK
*Correspondence to p.helliwell@Leeds.ac.uk The authors have declared no conflicts of interest EMJ. 2017;2[4]:134-139.
- [3]. Sirkka Liisa Hostikka, Jun Gong, and Ellen M. Carpenter[□]Axial and appendicular skeletal transformations, ligament alterations, and motor neuron loss in *Hoxc10* mutants Int J Biol Sci. 2009; 5(5): 397–410.Published online 2009 Jun 3.
- [4]. Shinya Yanagisawa,^{a,*} Naoki Sato,^b Masaki Shimizu,^c Kenichi Saito,^a Atsushi Yamamoto,^a and Kenji Takagishi^a Relation among the knee, sagittal spinal alignment, and the spinal range of motion: Investigation in local medical check-ups using the Spinal Mouse Asia Pac J Sports Med Arthrosc Rehabil Technol. 2015 Apr; 2(2): 68–71.
- [5]. Anna M. Wobser; Zachary Adkins; Randy W. Wobser. Anatomy, Abdomen and Pelvis, Bones (Ilium, Ischium, and Pubis)
- [6]. Claire M McVeigh, Andrew P Cairns,Diagnosis and management of ankylosing spondylitis BMJ. 2006 Sep 16; 333(7568): 581–585.
- [7]. Vishy Mahadevan **Anatomy of the vertebral column** Author links open overlay panel Volume 36, Issue 7, July 2018, Pages 327-332
- [8]. Guang Yang,[#] Benjamin B. Rothrauff,[#] and Rocky S. Tuan Tendon and Ligament Regeneration and Repair: Clinical Relevance and Developmental Paradigm Birth Defects Res C Embryo Today. 2013 Sep; 99(3): 203–222.

- [9]. CT Imaging for Evaluation of Calcium Crystal Deposition in the Knee: Initial Experience from The Multicenter Osteoarthritis (MOST) Study Devyani Misra,¹ Ali Guermazi,¹ Osteoarthritis Cartilage. 2015 Feb; 23(2): 244–248.
- [10]. David J Hunter, and David T Felson, osteoarthritis BMJ. 2006 Mar 18; 332(7542): 639–642
- [11]. Leticia Garcia-Montoya Recent advances in ankylosing spondylitis: understanding the disease and management 2018; 7: F1000 Faculty Rev-1512.
- [12]. Mikkel Østergaard and Robert G.W. Lambert Imaging in ankylosing spondylitis Ther Adv Musculoskelet Dis. 2012 Aug; 4(4): 301–311.
- [13]. Baraliakos X., Hermann K.G., Landewe R., Listing J., Golder W., Brandt J., et al. (2005) Assessment of acute spinal inflammation in patients with ankylosing spondylitis by magnetic resonance imaging: a comparison between contrast enhanced T1 and short tau inversion recovery (STIR) sequences. Ann Rheum Dis 64: 1141–1144 [PMC free article] [PubMed] [Google Scholar]
- [14]. Andrew McMichael¹ and Paul Bowness HLA-B27: natural function and pathogenic role in spondyloarthritis Arthritis Res. 2002; 4(Suppl 3): S153–S158.
- [15]. Susanne Juhl Pedersen¹, Walter P Maksymowych² The Pathogenesis of Ankylosing Spondylitis: an Update
- [16]. Yi-Fen Wang, Michael Mu-Huo Teng, Cheng-Yen Chang, Hung-Ta Wu and Shih-Tien Wang Imaging Manifestations of Spinal Fractures in Ankylosing Spondylitis American Journal of Neuroradiology September 2005, 26 (8) 2067-2076;
- [17]. Goldman L, et al., eds. Mechanical and other lesions of the spine, nerve roots and spinal cord. In: Goldman-Cecil Medicine. 25th ed. Philadelphia, Pa.: Saunders Elsevier; 2016. <https://www.clinicalkey.com>. Accessed March 7, 2017.
- [18]. Goodman CC, Fuller KS. Pathology Implications for the Physical Therapist. 3rd ed. St. Louis, MO: Saunders Elsevier; 2009.
- [19]. A T Masi, T A Medsger Jr A new look at the epidemiology of ankylosing spondylitis and related syndromes Clin Orthop Relat Res 1979 Sep;(143):15-29.
- [20]. Thomas GP, Brown MA: Genetics and genomics of ankylosing spondylitis. Immunol Rev. 2010, 233: 162-180.
- [21]. Overview of ankylosing spondylitis. Spondylitis Association of America. <https://www.spondylitis.org/Ankylosing-Spondylitis>. Accessed Oct. 2, 2019.
- [22]. Raychaudhuri SP, Deodhar A. The classification and diagnostic criteria of ankylosing spondylitis. J Autoimmun. 2014;48–49:128–33.
- [23]. Akhaddar A, Salami M. Fracture of the bamboo spine (chronic ankylosing spondylitis) after cervical injury. Pan Afr Med J. 2014;17: 113.
- [24]. de Vlam K, Mielants H, Veys EM. Involvement of the zygapophyseal joint in ankylosing spondylitis: relation to the bridging syndesmophyte. J Rheumatol. 1999;26:1738–1745.
- [25]. Eva Blozik, Wolfgang Himmel, Michael M. Kochen, Christoph Herrmann-Lingen, Martin Scherer. Sensitivity to change of the Neck Pain and Disability Scale. Spine. 2011;20:882-889.
- [26]. Rezvani A, Ergin O., Karacan I., Validity and reliability of the Metric Measurements in the Assessment of Lumbar Spine Motion in patients with Ankylosing Spondylitis., 2012, Lippincott Williams & Wilkins, SPINE vol 37
- [27]. Use of a numerical rating scale as an answer modality in ankylosing spondylitis-specific questionnaires. Van Tubergen A, Debats I, Ryser L, Londoño J, Burgos-Vargas R, Cardiel MH, Landewé R, Stucki G, Van Der Heijde D. Arthritis Rheum. 2002 Jun 15;47(3):242-8.
- [28]. Finbar D O'Shea¹, Reena Riarh, Annepa Anton, Robert D Inman Assessing back pain: does the Oswestry Disability Questionnaire accurately measure function in ankylosing spondylitis? 2010 Jun;37(6):1211-3. J Rheumatol
- [29]. Edwin Jauregui¹, Barbara Conner-Spady, Anthony S Russell, Walter P Maksymowych Clinimetric evaluation of the bath ankylosing spondylitis metrology index in a controlled trial of pamidronate therapy 2004 Dec;31(12):2422-8.
- [30]. Sophie Eyres¹, Alan Tennant Measuring disability in ankylosing spondylitis: comparison of bath ankylosing spondylitis functional index with revised Leeds Disability Questionnaire 2002 May;29(5):979-86
- [31]. S D Jones¹, A Steiner, S L Garrett, A Calin The Bath Ankylosing Spondylitis Patient Global Score (BAS-G) 1996 Jan;35(1):66-71.

- [32]. James T. Rosenbaum, M.D Evolving Diagnostic Criteria for Axial Spondyloarthritis Ocul Immunol Inflamm. 2016 Aug; 24(4): 445–449.
- [33]. Insight into the Quality of Life of Patients with Ankylosing Spondylitis: Real-World Data from a US-Based Life Impact Survey James T. Rosenbaum, Lisa Pisenti, Yujin Park & Richard A. Howard *Rheumatology and Therapy* **volume 6**, pages 353–367 (2019)
- [34]. Ankylosing spondylitis. National Institute of Arthritis and Musculoskeletal and Skin Diseases. http://www.niams.nih.gov/Health_Info/Ankylosing_Spondylitis. Accessed Oct. 2, 2019.
- [35]. Digital Spine Analysis (DSA) Before back pain can be treated it needs to be diagnosed correctly. Identifying and Isolating the root cause of the pain is essential to restoring mobility and function Get a Digital Spine Analysis or DSA
- [36]. <https://www.webmd.com/arthritis/ankylosing-spondylitis-17/daily-life/slideshow-ankylosing-spondylitis-exercises>
- [37]. https://www.hss.edu/conditions_steroid-side-effects-how-to-reduce-corticosteroid-side-effects.asp
- [38]. **Tumor Necrosis Factor Inhibitors** Valerie Gerriets; Pankaj Bansal
- [39]. Shea Carter, Kirsten Braem, and Rik J. Lories The role of bone morphogenetic proteins in ankylosing spondylitis *Ther Adv Musculoskelet Dis*. 2012 Aug; 4(4): 293–299.
- [40]. **Everything You Need to Know About Steroid Injections** Medically reviewed by Alana Biggers, M.D., MPH —Written by Erica Hersh on November 5, 2019
- [41]. What Are the Ayurveda Doshas? Vata, Kapha, and Pitta Explained Written by Katey Davidson, MScFN, RD on August 5, 2020
- [42]. <https://www.oneworldayurveda.com/what-is-panchakarma/>
- [43]. Gyanendra Shukla, Santosh K. Bhatted,¹ Alankruta R. Dave,² Efficacy of *Virechana* and *Basti Karma* with *Shamana* therapy in the management of essential hypertension: A comparative study 2013 Jan-Mar; 34(1): 70–76.
- [44]. Leticia Garcia-Montoya Recent advances in ankylosing spondylitis: understanding the disease and management 2018; 7: F1000 Faculty Rev-1512.

Mr. Saurabh Rajkumar Jadhav. “Ankylosing Spondylitis: Review and Current Treatments.” *IOSR Journal of Pharmacy (IOSRPHR)*, 11(02), 2021, pp. 40-50.