

Haematological and Biochemical findings of Hair Dye Poisoning

Awad Elkareem Abass¹, Noon mobasher¹, Fatima Ali¹, Randah Salah¹, Nada Mohamed¹

¹(Faculty of Medical Laboratory Sciences, University of Khartoum, Khartoum, Sudan)

Abstract: Background/aim: Hair dye containing paraphenylenediamine (PPD) is commonly used in Sudan as cosmetic agent. The direct toxic effect of PPD can lead to many pathological problems. Therefore, present study aimed to investigate some hematological and biochemical parameters in Sudanese who exposed to hair dye poisoning.

Patients/methods: A cross sectional hospital -based study was conducted in Ear-Nose-Throat (ENT) Hospital-Khartoum, 30 PPD- poisoned patients who were admitted for clinical management were enrolled in the study. Clinical manifestations were examined by clinician in the Hospital. Full blood count, renal function tests, and liver function tests were performed for each patient.

Results: Among the total included 30 patients, there were 27 (90%) females and 3(10%) were males. All patients were exposed to PPD via Oral route (100%). The main causes of exposure were suicidal attempts in (86.7%), accidental (13.3%). Types of dye used were Bigen (26.7%), Stone dye (26.7%) and Indian account about (46.6%). Clinical manifestation observed were; vomiting/abdominal pain 66.7%, edema of the face/neck 16.7%, swelling hard tongue 6.7%, chocolate brown urine 6.7%, and skin dermatitis 3.3%. Normocytic normochromic anaemia with reticulocytosis was detected in 3 (10%), leukocytosis (66.7%), prominent neutrophilia (83.3%), and neutrophil hyper-segmentation was observed in all cases (100%). Thrombocytopenia were observed in 10% , 96.7% had hairy platelets and anisocytosis. High levels of urea and creatinine were noticed in one patient (3%), hypokalemia in 30%, and hypernatremia in 10%. Elevated Liver enzymes were : AST 76.7%, ALT 46.7%, and ALP 10%. However, total protein were normal in all patients.

Conclusion: In Sudan, hair dye poisoning is more frequent among young adult female. Toxic effect of PPD poisoning causes morphological and numerical changes in all blood cells and some effect in liver and renal functions. Attention toward the health education programs to provide information on the risk of hair dyes poisoning, also support of analytical equipments that assist in the diagnosis and management of such cases.

Keywords - Hair dye, investigation, Laboratory, Poisoning, PPD, Signs.

Date of Submission: 12-7-2016

Date of acceptance: 07-12-2017

I. INTRODUCTION

Globally, suicide rate increases by 60% in 50 years in third world countries [1]. Hair dye containing paraphenylenediamine (PPD) have been reported as intentional and accidental causes of poisoning in Africa, the Middle-East, and the Indian subcontinent [2-5], where PPD is commonly mixed with Henna, which is traditionally applied to colour the hairs and paint the palms of hands in women [6]. In Sudan, hair dye is widely used for such purposes, different forms are available; stone hair dye and other branded hair dyes like Bigen and Black Henna are being the most common. All these forms are cheap and freely available in markets, making it an attractive agent for suicidal intent.

Depending on the dose and concentration of PPD; the direct toxic effect of hair dye through skin absorption, ingestion or inhalation can lead to damage of internal body organs and death. For this Hair dye is considered as the commonest suicidal tool in Sudan. PPD toxicity includes skin irritation, contact dermatitis, and lacrimation, or even blindness, due to local contact. Ingestion of PPD causes rapid development of severe cervico-facial oedema with respiratory distress, often requiring tracheostomy. Rhabdomyolysis and acute tubular necrosis supervene occur in the late phase [7]. Hypertension, convulsions, vomiting, and gastritis have been reported [8]. . Damage of muscular, renal, and hepatic systems also can occur [9].

Clinical management of patients is hampered by the lack of a rapid diagnostic test; no specific treatment other than supportive measures can be offered. Accidental and intentional causes of poisoning have been reported in Sudan before [3, 10-13]. However, most of the available literatures are cases reports. Thus, the study aimed to share our experience on clinical and laboratory findings of PPD poisoning among a group of exposed Sudanese.

II. PATIENTS AND METHODS

A cross sectional hospital based study was conducted in Ear-Nose-Throat (ENT) Hospital-Khartoum during a period of January to April 2013 after obtaining approval from Federal Ministry of Health and Hematology Department review board at FMLS- Khartoum University, Sudan. Thirty PPD -poisoned patients who were admitted for clinical management were enrolled. A written informed consent was obtained from each patient/his relatives, demographic and clinical data were recorded in a questionnaire. For each patient venous blood sample (5ml) was collected in EDTA container (2ml) for complete blood count using automated blood cell counter (Sysmex KX-21) and reticulocytes count, the rest of blood was drawn in lithium heparin container for renal function and liver function tests by automated chemical analyser (COBAS 6000 analyser, Roche). Results were analysed using SSPS software and Microsoft office (2007), then presented in figures and tables.

III. RESULTS

There were 27 (90%) females and 3(10%) males. Their ages range was 9 - 48 years old (mean was 24). All patients were exposed to PPD via Oral route (100%). The main causes of exposure were suicidal attempts in (86.7%), accidental (13.3%). Types of dye used were Bigen (26.7%), Stone dye (26.7%) and Indian account about (46.6%).

Clinical manifestations observed were; vomiting/abdominal pain 66.7%, oedema of the face/neck 16.7%, swelling hard tongue 6.7%, chocolate brown urine 6.7%, and skin dermatitis 3.3%.

Normocytic normochromic anaemia with reticulocytosis was detected in 3 (10%), leukocytosis (66.7%), prominent neutrophilia (83.3%), and hyper-segmentation was observed in all patients' neutrophils (100%). Thrombocytopenia were observed in 10% of cases, 96.7% had hairy platelets and anisocytosis. High levels of urea and creatinine were noticed in one patient (3%), hypokalemia in 30%, and hypernatremia in 10%. Elevated Liver enzymes were as follow: AST 76.7%, ALT 46.7%, and ALP 10%. However, total protein levels were normal in all patients.

TABLE.1. CLINICAL MANIFESTATION AT PRESENTATION AMONG THE STUDY POPULATION

Clinical Manifestation	NO. of patients (30)	Percent %
vomiting/Abdominal pain	20	66.7
Oedema of face and neck	5	16.7
Swollen hard tongue	2	6.7
Chocolate brown urine	2	6.7
Skin dermatitis	1	3.3

TABLE.2. LABORATORY FINDINGS AT PRESENTATION AMONG THE STUDY POPULATION

Hematological/Biochemica Findings	NO. of patients (30)	Percent %
Normocytic Anemia	3	10
Leucocytosis	20	66.7
Neutrophilia	25	83.3
Hypersegmented neutrophils	30	100
Thrombocytopenia	3	10
platelets anisocytosis	29	96.7
High urea	1	3.3
High creatinine	1	3.3
Hypernatremia	3	10
Hypokalemia	9	30
Norma Total protein	30	100
High AST	23	76.7
High ALT	14	46.7
High ALP	3	10

TABLE.3. MEAN± SD OF THE STUDIED HEMATOLOGICAL AND BIOCHEMICAL PARAMETERS

Parameter	Mean± SD	Std. Error
Hb g/dl	12.6± 1.36	0.25
TWBCs cell/ μ l	10.68± 4.53	0.84
Platelets cell/ μ l	309± 101	19
Absolute Neutrophils/ μ l	8.5± 6.5	1.3
Absolute Lymphocytes/ μ l	1.35± 0.79	0.14
Absolute Mixed/ μ l	0.64± 0.78	0.14
Urea mg/dl	27± 21.6	3.9
Creatinine mg/dl	0.9± 1.13	0.2
Na ⁺ mmol/l	144± 11.7	2.18
K ⁺ mmol/l	3.8± 0.69	0.12
AST u/l	2137± 430	76
ALP u/l	1056± 147	26
ALT u/l	1637± 331	60
Total protein g/dl	7.5± 0.89	0.16

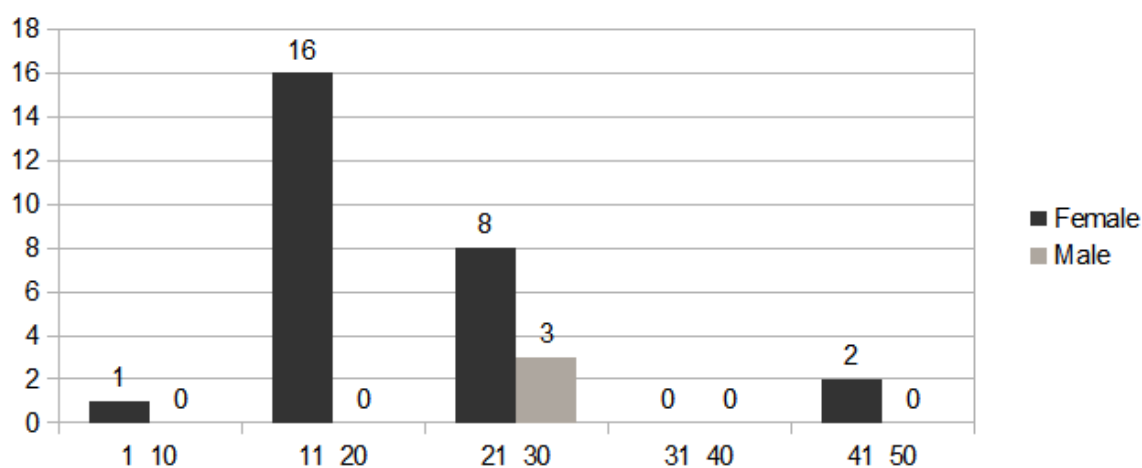


FIG.1. DISTRIBUTION OF AGE/YEAR AND GENDER AMONG THE STUDY POPULATION

IV. DISCUSSION

The study included 30 cases who were exposed to hair dye poisoning; the majority were females who were mostly exposed to dye -via oral route -intentionally as suicidal attempt for many reasons like depressions. All patients received some level of clinical management. The majority of poisoned cases were females (N/27); young adults were 24 cases (Age's mean was 21), old ladies were 2 cases (their ages range 41-50), and one was child (9 years old). There were female preponderance of 80.7% as per Hamdouk [14], and 77% as per Filali et al [2]. It was 90% in the present study. Suicidal in 86.7% as per Hamdouk (87%) [14] and 78.1% as per Filali et al [2]. In this study, the common affected age group was 18 to 30 years in 27(90%) cases (24 females and 3 males). Radhika et al [15] in their study found that the common age group effected were 15 to 35 years.

Among the studied female group; 40.7% were married and 59.3% were single student. Among the 26 patients who were exposed to Hair dye in suicidal way; there were 3 psychiatric females. Elgamel et al [16] found that about 51% of their cases had history of psychological problems. The effects of PPD when ingested are serious and can cause damage to the respiratory, muscular, renal, and hepatic systems and cause death [3]. The clinical outcomes of PPD poisoning and its severity vary from one patient to another depending on the route of exposure, dose and concentration of hair dye [17]. Large dose can cause death within the first 6-24 hrs due to angioneurotic oedema or cardio-toxicity leading to fatal arrhythmias, smaller dose or if the patient vomited most of ingested dye usually presents with angioneurotic oedema with no further problem. In this study, most of the poisoned patients (66.7%) were presented with vomiting and abdominal pain, while other signs were observed

in few cases. Chocolate brown urine were indicative for haemoglobinuria as result of haemolysis; our findings revealed normocytic normochromic anaemia with reticulocytosis in 3 patients (10%). Most of the cases had leucocytosis and the majority had prominent neutrophilia, same findings were reported by Anugrah et al [18]. Thrombocytopenia was detected in 10%, hairy platelets and anisocytosis in 96.7% of the cases. The exact mechanisms of PPD- induced thrombocytopenia has not been investigated, but may be due to direct toxic effect of dye on platelets facilitating their destruction. Many published case reports indicated that hair dyes has toxic effect on the bone marrow and can suppress the production of blood cells [19, 20]. In this study, assessment of some biochemical parameters revealed impairment in renal and liver functions to some extent depending on the level of patient management at time of blood sampling. One patient poisoned with a moderate dose of stone hair dye was presented with acute renal failure, had a high level of urea and creatinine, and this agreed with several studies conducted in Sudan [10, 11, 16]. Elevated renal parameters, AST, ALT, suggested the development of acute kidney injury due to rhabdomyolysis [17].

Hypokalemia (30%) and Hypernatremia (10%) were also detected; same results were reported by Kallel et al [4]. Elevated levels of AST (66.7%), and ALT (46.6%), and ALP (10%) were suggestive of liver muscles injury, this agreed with a study done by Anugrah et al [18]. However, total protein levels were normal in all patients.

V. CONCLUSION

We reached to conclude that hair dye poisoning is common among Sudanese, more frequent among young adult females. PPD poisoning has toxic effect on blood cells; renal impairment and liver dysfunction are involved. Awareness program should be established to provide information on the risk of hair dyes exposure in different ways of uses. Investigation of full blood count, renal and liver functions should be included in routine tests for management of hair dye -poisoned patients.

ACKNOWLEDGEMENTS

Authors are grateful to all subjects who participated in this study, special thanks to all medical staff in ENT Hospital - Khartoum for their help and cooperation..

REFERENCES

- [1]. Sampathkumar K, Sooraj YS, Mahaldar AR, Ajeshhkumar RP, Muthiah R. Hair dye poisoning: An emerging threat. *Indian J Crit Care Med*, 11, 2007, 212-214.
- [2]. Ayoub Filali, I. Semlali, V. Ottaviano, C. Furnari, Danilo Corradini, Rachida Soulaymani. A retrospective study of acute systemic poisoning of paraphenylenediamine (occidental takawt) in Morocco. *Afr J Tradit Complement Altern Med*, 39, 2006, 142–149.
- [3]. Suliman SM, Fadlalla M, Nasr Mel M, et al. Poisoning with hair-dye containing paraphylene diamine: ten years experience. *Saudi J Kidney Dis Transpl*, 6, 1995, 286–289.
- [4]. Kallel H, Chelly H, Dammak H, et al. Clinical manifestations of systemic paraphenylene diamine intoxication. *J Nephrol*, 18, 2005, 308–311.
- [5]. Ashar A. Acute angioedema in paraphenylenediamine poisoning. *J Pak Med Assoc*, 53, 2003, 120-122.
- [6]. Sumeet Singla, Sanjeev Miglani, A K Lal, Pulin Gupta, A K Agarwal. Para-phenylenediamine (PPD) Poisoning. *JACM*, 6(3), 2005, 236-238.
- [7]. PK Jain, N Agarwal, P Kumar, NS Sengar, Nutan Agarwal, Asif Akhtar. Hair Dye Poisoning in Bundelkhand Region (Prospective Analysis of Hair Dye Poisoning Cases presented in Department of Medicine, MLB Medical College, Jhansi). *JAPI*, 59, 2011, 415-419.
- [8]. MacPhee DG, Podger DM. Hair dyes (Correspondence). *Med J Aust*, 2 (1), 1975, 33.
- [9]. Nohynek GJ, Fautz R, Benech-Kieffer F, Toutain H. Toxicity and human health risk of hair dyes. *Food Chem. Toxicol.*, 42(4), 2004, 517–543.
- [10]. Kaballo BG, Khogali MS, Khalifa EH, Khaiii EA, Ei-Hassan AM, Abu-Aisha H. Patterns of "severe acute renal failure" in a referral center in Sudan: excluding intensive care and major surgery patients. *Saudi J Kidney Dis Transpl*, 18(2), 2007, 220-225.
- [11]. Abdelraheem MB, El-Tigani MA, Hassan EG, Ali MA, Mohamed IA, Nazik AE. Acute renal failure following to paraphenylene diamine hair dye poisoning in Sudanese children. *Ann Trop Paediatr*, 29(3), 2009, 191-196.
- [12]. Abdelraheem M, Ali el-T, Hussien R, Zijlstra E. Paraphenylene diamine hair dye poisoning in an adolescent. *Toxicol Ind Health*, 27(10), 2011, 911-913.
- [13]. Abdelraheem MB, Elbushra M, Ali ET, et al. Filicide and suicide in a family by paraphenylene diamine poisoning: A mother who committed suicide and poisoned her four children of which one died. *Toxicol Ind Health*, 30(8), 2014, 679-682.
- [14]. Mohamed I. Hamdouk, Mohamed B. Abdelraheem, Ahabab A. Taha, Mohamed Benghanem and Marc E. De Broe. Paraphenylene diamine hair dye poisoning. *Clinical Nephrotoxins*, 3, 2008, 871-879.

- [15]. Radhika. D, Murali Mohan K. V, Sreenivasulu M, Srikanth Reddy Y, Karthik T. S. *J Biosci Tech*, 3 (4), 2012, 492- 497.
- [16]. Elgamel A. A., Ahmed N. O. Complications and management of hair dye poisoning in Khartoum. *Sud Med Monitor*, 8(3), 2013, 146-152.
- [17]. Namburi Rajendra Prasad, Aparna Rajeshwar Rao Bitla, Suchitra Musturu Manohar, N Harini Devi, PVLN Srinivasa Rao. A Retrospective Study on the Biochemical Profile of Self Poisoning with a Popular Indian Hair Dye. *J Clin and Diag Res*, 5(7), 2011, 1343-1346.
- [18]. Anugrah Chrispal, Anisa Begum, Ramya, Anand Zachariah. Hair dye poisoning - an emerging problem in the tropics: An experience from a tertiary care hospital in South India. *Trop Doct*, 40(2), 2010, 100-103.
- [19]. Hopkins, J.E. and Manoharan, A. Severe Aplastic Anaemia Following the Use of Hair Dye: Report of Two R. Naseer, A. Ghani 279 Cases and Review of Literature. *Postgraduate Med J*, 61, 1985, 1003-1005.
- [20]. Burnett, C.M., Corbett, J.F. and Lanman, B.M. Hair Dyes and Aplastic Anemia. *Drug and Chem Toxicology*, 1, 1977, 45-61.

Awad Elkareem Abass "Haematological and Biochemical findings of Hair Dye Poisoning."
IOSR Journal of Pharmacy (IOSRPHR), vol. 7, no. 12, 2017, pp. 00-00

IOSR Journal of Pharmacy (IOSR-PHR) is UGC approved Journal with Sl. No. 5012