

Arteriovenous Malformation Of The Uterus

M.M Begum, S. Sultana, M.A Hossain, M. Quddus

Correspondence to: Dr. Mst. Moonmoon Begum, Resident Surgeon, Rangpur Medical college hospital.

Corresponding Author: M.M Begum

Abstract: Uterine Arteriovenous malformations (UAVM) are uncommon entities and should be considered in patients who present with profuse genital tract bleeding. There are two types of uterine AVM: acquired and congenital. Acquired uterine AVMs are conformed by communications between the uterine arteries and the myometrial veins, and are caused by an iatrogenic event or a pathological condition. Congenital AVMs are the result of abnormal development of primitive vessels that result in connections between pelvic arteries and veins in the uterus without an interconnecting capillary bed. Initial evaluation of UAVMs is made with ultrasonography (US) and US-Doppler. MRI is used when a UAVM is suspected at US. Treatment can be surgical (hysterectomy or surgical removal of AVM), or with selective uterine arterial embolization. We report a case of abnormal uterine bleeding due to UAVM.

Keywords: Arterio-venous malformation, US-Doppler, MRI, Embolization, Genital bleeding, uterine artery.

1. Dr. Mst. Moonmoon Begum, Resident Surgeon, Department of Obstetrics & Gynecology, Rangpur Medical College Hospital.
2. Dr. Sharmin Sultana, Associate Professor, Department of Obstetrics & Gynecology, Rangpur Medical College Hospital.
3. Dr. Md. Anwar Hossain, Associate Professor, Department of Surgery, Rangpur Medical College & Hospital.
4. Dr. Maliha Quddus, Assistant Register, Department of Obstetrics & Gynecology, Rangpur Medical College Hospital.

Date of Submission: 10-01-2017

Date of acceptance: 09-12-2017

I. INTRODUCTION

Uterine Arteriovenous vascular malformations (UAVMs) are uncommon vascular disease, which usually occur during reproductive age.¹ Patients affected by UAVMs usually present with recurrent pregnancy loss or menorrhagia. UAVM is a rare but potentially life threatening source of bleeding. Uterine AVMs are characterized by multiple communications of varying sizes between arteries and veins in same vicinity. Uterine AVMs have been classified as congenital and acquired.²

Congenital uterine AVMs arise from an abnormality in the embryological development of primitive vascular structures, resulting in multiple abnormal communications between arteries and veins.² Acquired uterine AVMs are usually traumatic, resulting from prior dilatation and curettage (D&C), uterine surgery or direct uterine trauma, and less commonly from endometrial carcinoma, cervical carcinoma and gestational trophoblastic disease.

The classical presentation of uterine AVM is often one of severe uterine bleeding with no obvious cause. Other symptoms include lower abdominal pain, dyspareunia, and anaemia secondary to blood loss.

Several imaging methods, such as Doppler ultrasonography, computed tomography (CT), magnetic resonance imaging (MRI), and angiography, have been employed to diagnose AVMs. Angiography is the gold standard for diagnosis, whereas Doppler ultrasonography and MRI are the modalities of choice for the evaluation of a suspected AVM.

Prior to embolotherapy, conservative treatment, such as expectant management and medication, hysterectomy or uni/bilateral uterine artery ligation were the therapies of choice. Embolotherapy, which offers the major advantage of fertility preservation, has become a well recognized alternative to surgical intervention for treating uterine AVMs.

The current case report presents a patient with uterine AVM initially diagnosed with Doppler US and cannot be confirmed by angiography due to unavailability of the facility and poverty of the patient and treated by hysterectomy.

Case Report

A 23-year-old woman para 1, suffering from abnormal uterine bleeding for several months and unresponsive to conventional medical treatment by hormone therapy, was admitted in Rangpur medical college hospital with menorrhagia and severe anemia. She had undergone a vaginal delivery 7 years back and gave no history of abortion or uterine evacuation and curettage. Her menstrual cycle was regular after menarche, at an interval of 28 days, and bleeding last for about 5 days. For the last 1 year she was suffering from menorrhagia and irregular cycles. She was treated by gynecologist several times but her condition was not improved. The patient was hospitalized for an abundant metrorrhagia, with hemoglobin level dropping to 4 gm/dl and on admission she received blood transfusions for correction of anemia. General examination of the woman was normal except for a severely anemic appearance. Pelvic examination showed uterus was normal in size and no adnexal abnormality was detected on palpation. The vulva, vagina and cervix were also normal. She was normotensive, non-diabetic, her thyroid function tests, coagulation profiles and serum B-hCG were within normal range. Transabdominal US was performed showing normal sized uterus, cervix was broad, multiple grossly dilated engorged vessels filled with blood noted in both cervix and also in body and fundus of the uterus on Doppler study, highly suggestive of uterine AVM. There was no facility for interventional radiology for pelvic angiography and uterine artery embolization in our center. So, the patient was referred to higher center, but she was very poor to bear the expenses and denied to go to higher facility. Then total abdominal hysterectomy was done after proper counseling and informed consent.

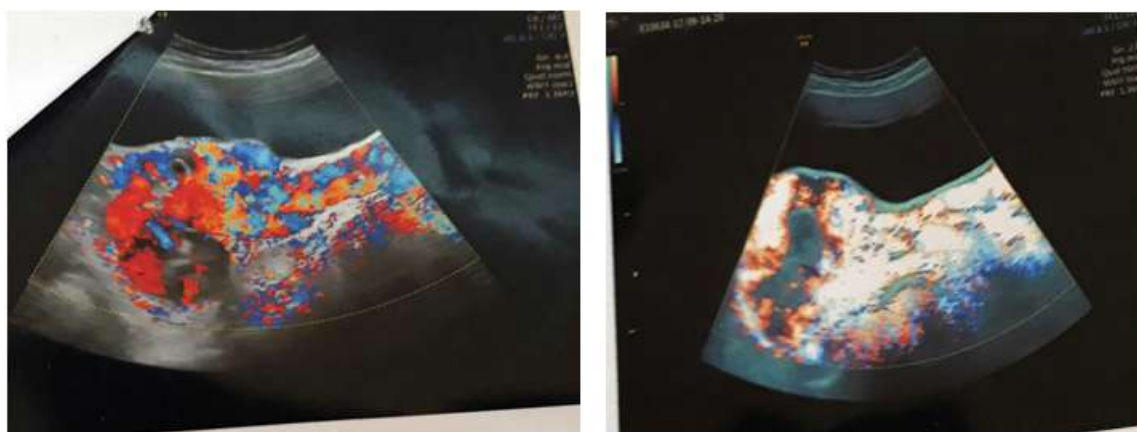


Figure 1: Color Doppler imaging features of uterine arteriovenous malformation (AVM) showing mosaic pattern and turbulent flow.

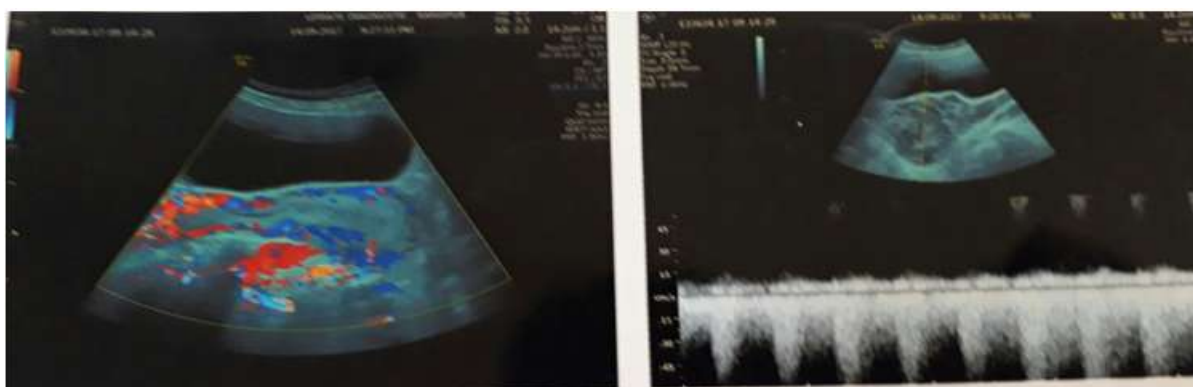


Figure 2: US-Doppler shows high flow vessels within uterine lesions and spectral analysis shows arterial flow with diastolic component.

II. DISCUSSION

Uterine arteriovenous malformations (UAVMs) are an uncommon vascular disease and represent 2% of all genital and intraperitoneal haemorrhages.¹ Dubreli and Loubat first described them in 1926 as cirroid aneurisms, and since then they had been referred as Arteriovenous aneurysm or Arteriovenous malformations.^{3,4}

UAVM can be congenital or acquired. Congenital lesions are rare. Acquired lesions are related to previous surgery on the uterus and rare as endometrial adenocarcinoma, maternal diethylstilbestrol exposure, miscarriage, uterine infections, myomas, endometriosis, intrauterine devices and trophoblastic disease.

An AVM consists of a proliferation of heterogeneous sized vascular channels with an arteriovenous fistula formation.¹

Congenital UAVMs tend to have multiple vascular connections and to invade the surrounding structures, while acquired UAVMs are confined within the myometrium and/or the endometrium showing direct communication between the intramural branches of the uterine artery and the myometrial veins.⁵

UAVM usually occurs during reproductive age. Common clinical signs are bleeding which is typically intermittent and abundant, pelvic pain and signs of anemia.⁶ Clinical examination can be unremarkable or showing a palpable mass at vaginal examination.⁷

Initial evaluation of UAVMs is made with ultrasonography (US), at which they appear either as masses with multiple hypo/anechoic tubular like structures of varying sizes or as focal endometrial and myometrial thickenings. US-Doppler adds the possibility of recognizing vessels within malformations. Spectral analysis permits evaluating the flow within vessels, recognizing high flow and low resistance index within arteries and veins.^{3,5}

In case of suspected UVAM at US, Serum b-Hcg is recommended to exclude a gestational trophoblastic disease (GTD), since US findings in UAVM may mimic those of GTD.¹

Magnetic resonance (MR) is used when a UAVM is suspected at US. Typical MR findings are a bulky uterus with absence of a defined mass and the presence of serpiginous and dilated vessels within myometrium or parametrium.⁸

Conventional angiography remains the gold standard imaging technique, although MRA has proven to be comparable to conventional angiography in evaluation of AVM.⁹ Arteriography shows dilated irregular vascular spaces supplied by enlarged uterine arteries, with high flow vascular dynamics.⁵

Treatment can be surgical (Hysterectomy or surgical removal of AVM), or with selective uterine artery embolization (UAE).^{5,6,9} Preferred treatment is selective UAE.⁹ Surgery should be reserved for those cases in which UAE is not feasible or is contraindicated. Medical treatment with combined oral contraceptive pill has been reported in literature.⁸

III. CONCLUSION

Uterine Arteriovenous malformation should be suspected in patient with abnormal uterine bleeding, especially who had the past medical history including caesarean section, induced abortion, dilatation and curettage and so on. Although angiography remains the gold standard, Doppler ultrasonography is also a good non-invasive technique. The transcatheter uterine artery embolization offers a safe and effective treatment.

REFERENCES

- [1]. Cura M, Martinez N, Cura A, Dalsaso TJ, Elmerhi F, (2009) Arteriovenous malformations of the uterus. *Acta Radiol* 50(7): 823-829.
- [2]. Huang MW, Muradali D, Thurston WA, Burns PN, Wilson SR. Uterine Arteriovenous malformations: gray-scale and Doppler US features with MR imaging correlation. *Radiology* 1998; 206: 115-123.
- [3]. Polat P, Suma S, Kantarcy M, Apler F, Levent A (2002) Color Doppler US in the evaluation of uterine vascular abnormalities. *Radiographics* 22(1): 47-53.
- [4]. Dubreuil G, Loubat E (1926) Aneurysme cirsoide de l' uterus. *Ann Anat Pathol* 3: 697-718.
- [5]. Nicholson AA, Turnbull LW, Coady AM, Guthrie K (1999). Diagnosis and management of uterine arterio-venous malformations. *Clin Radiol* 54: 265-269.
- [6]. Brown JV 3rd, Asrat T, Ebstein HD, Oglevie S, Goldstein BH (2008). Contemporary diagnosis and management of uterine arteriovenous malformations. *Obstet Gynecol* 112 (2 pt 2): 467-470.
- [7]. Sanguin S, Lanta-Delmas S, Le Blanche A, Grardel-Chambenoit E, Merviel P, Gondry J et al (2011) Uterine arterio-venous malformations: diagnosis and treatment in. *Gynecol Obstet Fertil* 39(12): 722-727.
- [8]. Grivell RM, Reid KM, Mellor A (2005) uterine arterio-venous malformations: a review of the current literature. *Obstet Gynecol Surv* 60: 761-767.
- [9]. Vogelzang RL, Nemcek AA Jr, Skrtic Z, Gorrell J, Lurain JR (1991) Uterine arteriovenous malformations: primary treatment with therapeutic embolization. *J Vasc Interv Radiol* 2:517-522.

IOSR Journal of Pharmacy (IOSR-PHR) is UGC approved Journal with SI. No. 5012

M.M Begum. "Arteriovenous Malformation Of The Uterus." *IOSR Journal Of Pharmacy* www.Iosrphr.org, vol. 08, no. 01, 2018, pp. 44-46.